

Peter J. Grahn, Ph.D.¹, Jonathan Calvert², Igor Lavrov, M.D., Ph.D.¹, Dimitry Sayenko³, Meegan van Straaten⁴, Megan Gill⁴, Jeffrey Strommen, M.D.⁴, Dina Drubach¹, Lisa Beck⁴, Margaux Linde⁴, Andrew Thoreson⁴, Cesar Lopez⁴, Aldo Mendez, M.D.¹, Parag Gad, Ph.D.³, Yury Gerasimenko, Ph.D.³, Reggie Edgerton, Ph.D.³, Kristin Zhao, Ph.D.^{4,5}, Kendall H. Lee, M.D., Ph.D.^{1,4,5}

1. Department of Neurologic Surgery, Mayo Clinic, Rochester, MN 2. Mayo Clinic Graduate School of Biomedical Sciences, Mayo Clinic, Rochester, MN 3. Department of Integrative Biology and Physiology, University of California Los Angeles, Los Angeles, CA 4. Department of Physical Medicine and Rehabilitation, Mayo Clinic, Rochester, MN 5. Department of Physiology and Biomedical Engineering, Mayo Clinic, Rochester, MN

Background

Severe spinal cord injury (SCI) leads to functional disconnection of ascending and descending spinal pathways.

Epidural electrical stimulation (EES) has previously facilitated volitional control of joint-specific muscles and independent standing after months of training in patients with SCI (Harkema 2011, Angeli 2014).

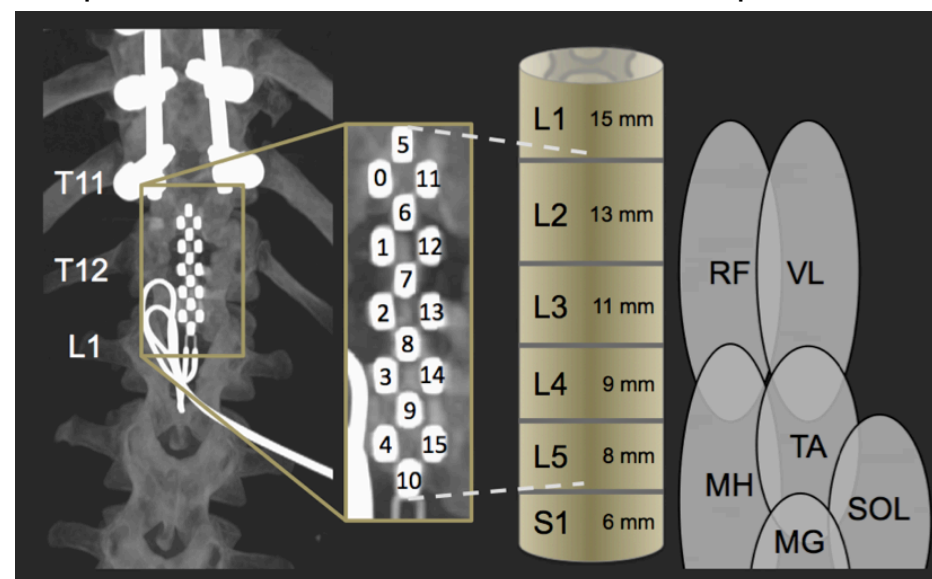
Here, we report a case of chronic traumatic paraplegia in which EES of the lumbosacral spinal cord enabled: 1) volitional control of task-specific muscle activity; 2) volitional control of rhythmic muscle activity to produce step-like movements while side-lying; 3) independent standing; 4) and while in a vertical position with body weight partially supported, voluntary control of step-like movements and rhythmic muscle activity.

This is the first time the application of EES enabled all of these tasks in the same subject within the first two weeks (eight stimulation sessions total) of EES therapy.

Methods

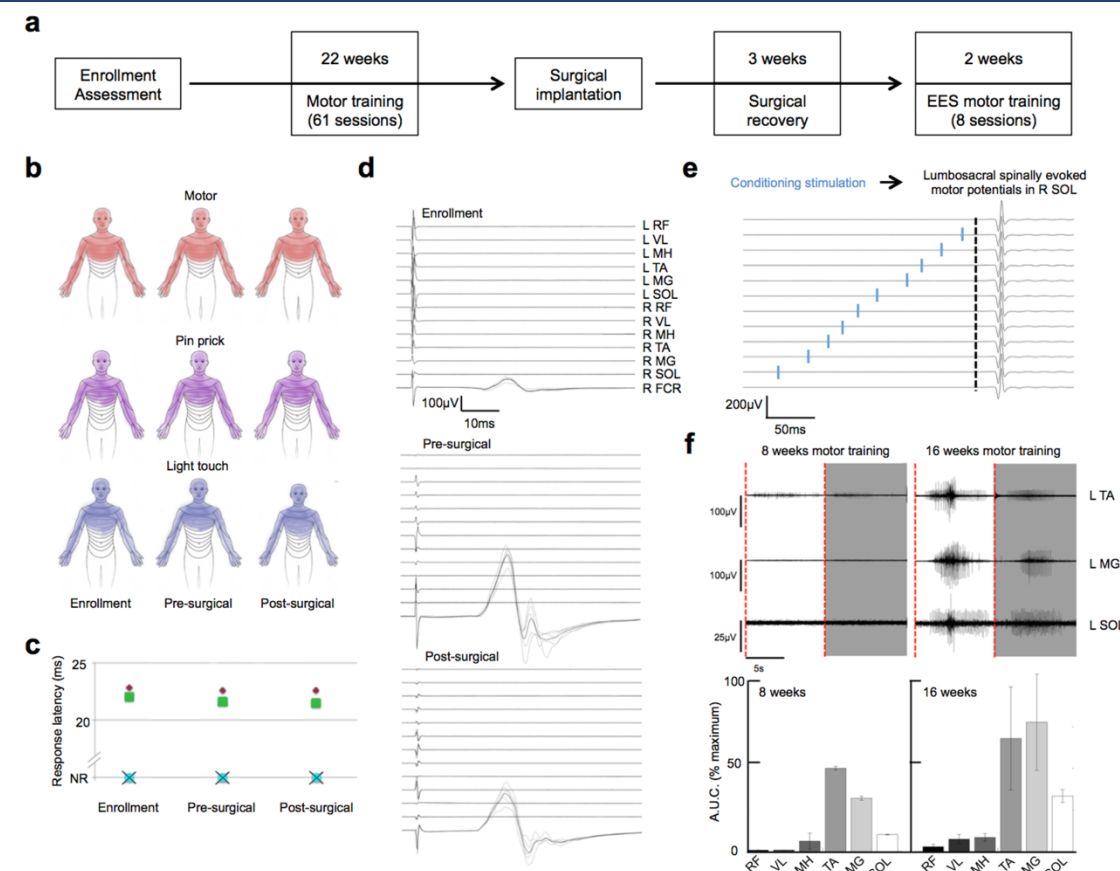
The participant was a 26-year-old male who sustained a traumatic T6 ASIA-A SCI three years prior.

After 22 weeks of motor training, an EES system was implanted in the region of the lumbar enlargement, followed by three weeks of post-operative recovery and eight sessions of volitional motor performance testing in the presence of EES over a two-week time period.



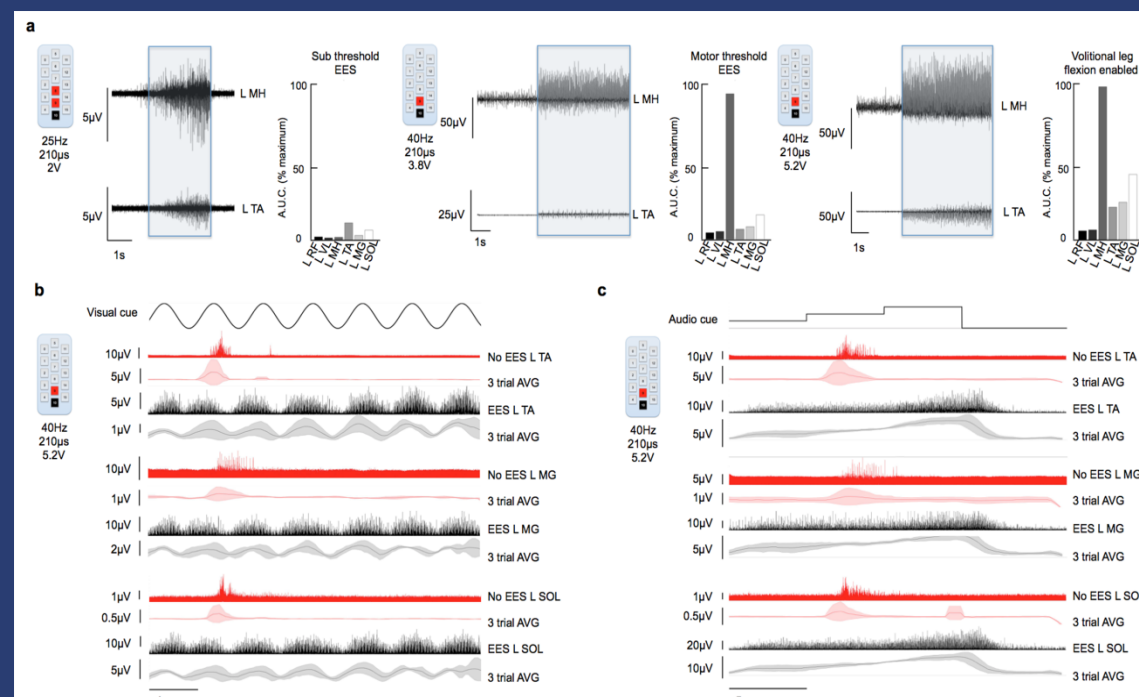
Muscle activity was recorded via surface EMG electrodes, and data were sampled at 4 kHz.

Study Timeline and Injury Profile



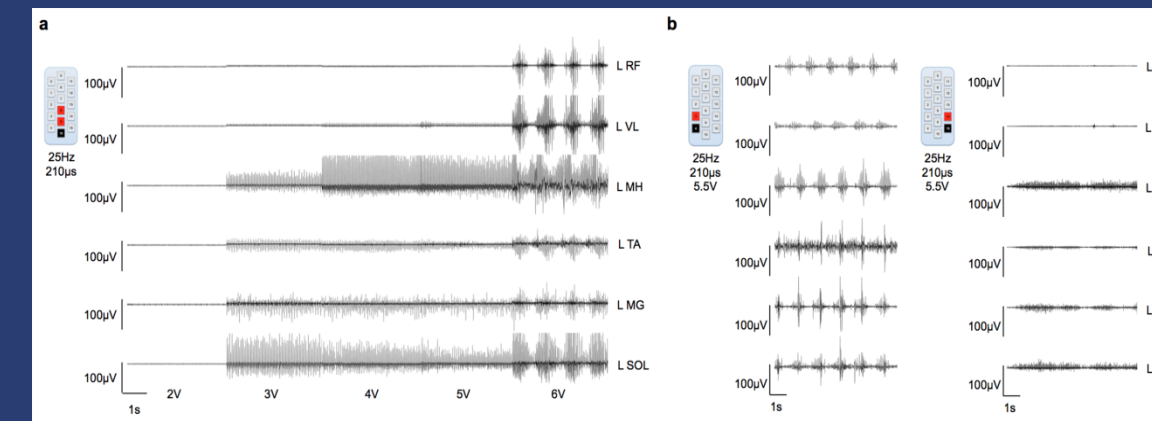
(b) Shaded regions depict ASIA motor, pin prick and light touch scores across assessments
 (c) Somatosensory evoked potential latencies show normal responses below injury, no responses at cortical level
 (d) MEPs were not observed during TMS in any leg muscles
 (e) No change in brain spinal cord connectivity tests
 (f) Evidence of discomplete SCI

Volitional Control of Task-Specific Muscle Activity



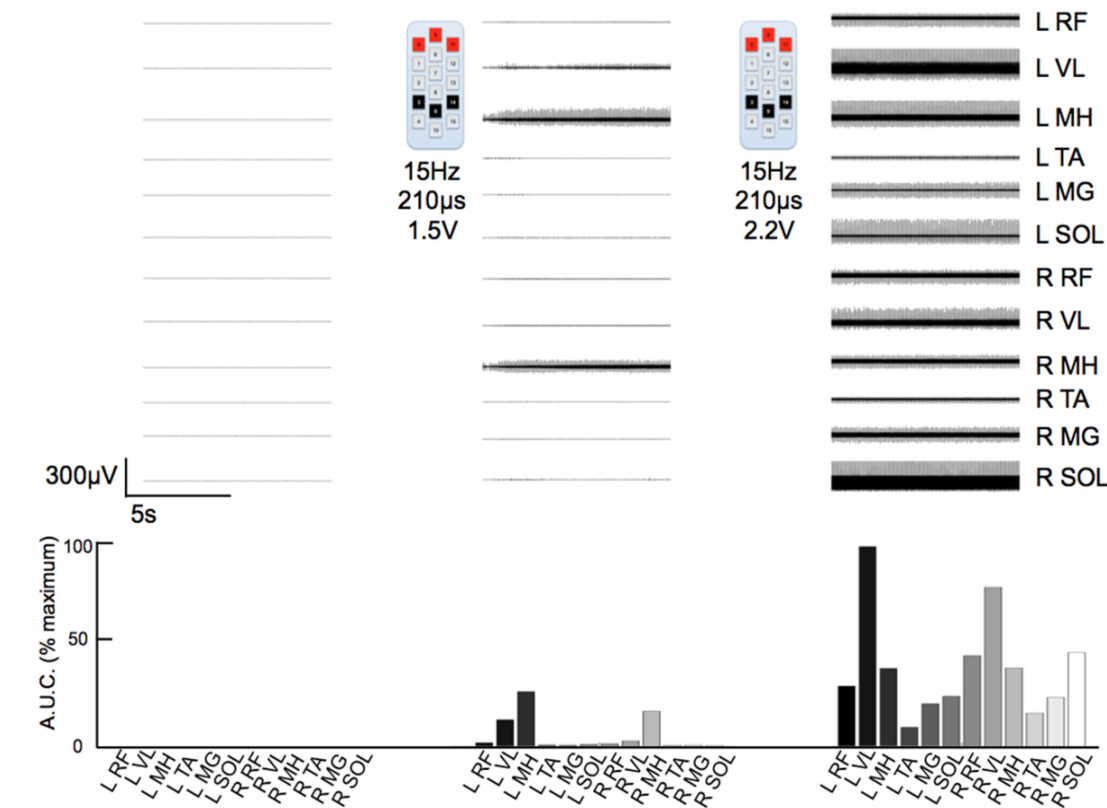
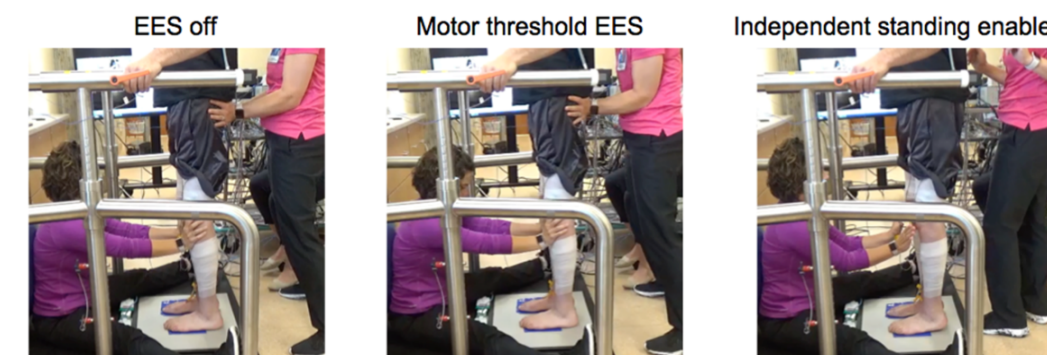(a) EMG recordings are shown during attempts to volitionally perform leg flexion in the presence of EES
 (b) EMG recordings during attempts to volitionally contract lower limb muscles in the presence of EES with a visual display of a sinusoidal cue without (red plots) and with EES (black plots).
 (c) EMG recordings during attempts to volitionally contract during an audio cue consisting of three increasing intensities without (red plots) and with EES (black plots).

EES parameters that enable rhythmic motor activity in side-lying



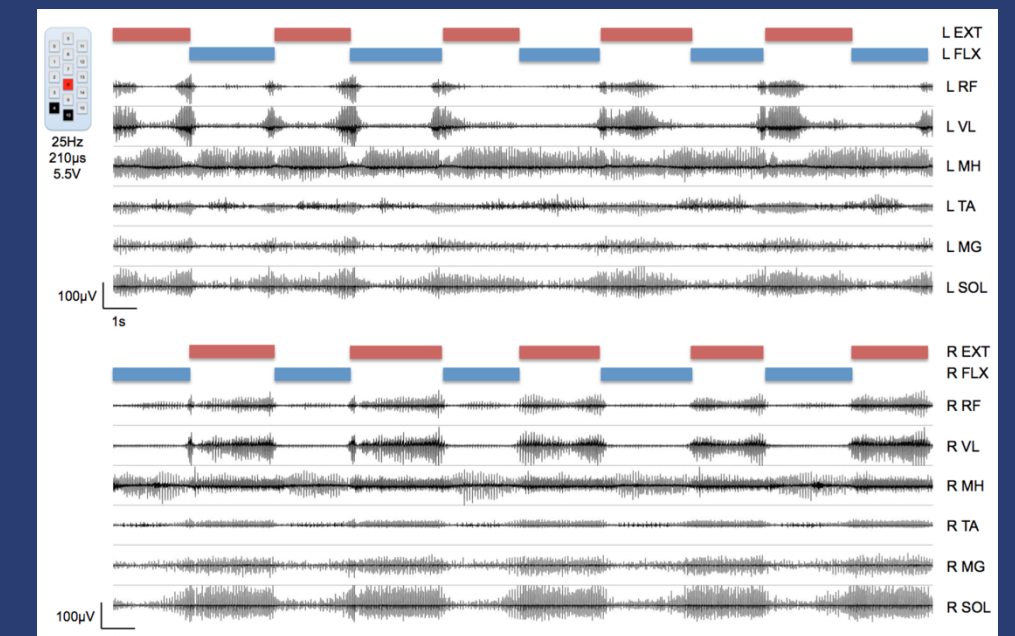
(a) Left leg EMG while increasing EES from two to six volts (v) is shown with subject lying on his right side with left leg elevated.
 (b) Active electrodes positioned laterally enabled rhythmic activity in the limb ipsilateral to stimulation (left plot). Shifting active electrodes to the contralateral side of the array did not facilitate rhythmic EMG in the ipsilateral leg.

EES-facilitated independent standing



Without EES, trainer support was required at the pelvis and knees. During threshold EES, trainer assistance was required at the knees with minimal support at the pelvis. At increased EES voltage intensity, independent standing was achieved for over 1.5 minutes.

Bilateral Step-Like EMG Activity in Upright Position



EMG recordings from the left and right leg are shown for five cycles of volitional extension and flexion bilaterally in the presence of EES.

Conclusions

This report provides evidence of successful replication of previously reported results that:

1. EES enabled volitional control of motor activity
2. EES enabled independent standing after several months of training, in two ASIA-A and two ASIA-B subjects

In addition, this is the first report of EES-facilitated volitional control of task-specific motor activity and control of rhythmic step-like movements within a single subject with clinically complete chronic SCI during the first two weeks of EES.

References

Harkema S, et al. Effect of epidural stimulation of the lumbosacral spinal cord on voluntary movement, standing, and assisted stepping after motor complete paraplegia: a case study. *The Lancet*. 2011.
 Angeli CA, et al. Altering spinal cord excitability enables voluntary movements after chronic complete paralysis in humans. *Brain*. 2014.
 Grahn PJ, et al. Enabling task-specific volitional motor functions via spinal cord neuromodulation in a human with paraplegia. *Mayo Clinic Proceedings*. 2017.

Acknowledgements

Support provided by the Broccoli Foundation, Christopher and Dana Reeve Foundation, Mayo Clinic Center for Clinical and Translational Sciences, Mayo Clinic Rehabilitation Medicine Research Center, Mayo Clinic Transform The Practice, Regenerative Medicine Minnesota, Craig H. Neilsen Foundation, Bel13ve in Miracles Foundation, and The Grainger Foundation.